

Effect of Perioperative Hyperbaric Oxygen on Bruising in Face-lifts

Hyperbaric oxygen (HBO) therapy has been used for wound healing for many years. It increases the ability of blood to upload, carry, and deliver oxygen to tissue. The mechanism by which oxygen acts on wound beds is multifactorial, but includes improved oxygen delivery to relatively hypoxic and

avascular tissue and increases free radical scavengers to prevent and reduce oxidative stress and tissue injury. The final common pathway for wounds treated with HBO therapy is improved and more rapid wound healing.

Wound healing is a primary interest of both patients and the collective health care industry. Physicians modify surgical techniques, pharmaceutical companies spend millions of dollars on research and development, and patients use anecdotal home remedies in their care to facilitate a more rapid recovery. One of the most challenging aspects in evaluation of wound healing has been developing an inexpensive, easy-to-use, objective measure to assess outcomes. Subtle variability between photographs may be imperceptible to even the most trained eye, resulting in inaccuracies when grading outcomes.¹⁻³ Seeley et al⁴ developed digital photographic analysis of ecchymosis of the skin flaps of patients who undergo face-lift procedures using nonsurgical internal skin controls to reduce intraobserver variability.

We present a prospective controlled trial using the digital photography computer model by Seeley et al⁴ to analyze color variability and assess the effect of perioperative HBO on bruising in face-lift surgery.

Methods. Thirteen patients were entered into the study from the senior author's practice (A.A.J.). All 13 patients were offered the opportunity to participate in the treatment arm. Informed consent was obtained from the 6 patients choosing to undergo HBO therapy. Drains and dressings were removed on postoperative day (POD) 1. All patients received routine postoperative care, which includes oral steroids, prophylactic antibiotics, the botanical *Arnica montana*, and bromelain. The treatment group received 5 perioperative HBO treatments at 2 atmospheres for 60 minutes administered on the 2 days prior to surgery and then again on PODs 3, 4, and 5. Standard digital photography was taken on PODs 1, 5, 7, and 10 for digital analysis.

Each photograph underwent digital analysis using Adobe Photoshop (Adobe Systems Inc, San Jose, California) in the CMYK (cyan, magenta, yellow, and black; see Seeley et al⁴ for a detailed description) color mode from the image drop-down menu with the internal control of normal skin and the surgically treated cheek soft tissue evaluated.

The CMYK color mode was used as previously described by Seeley et al,⁴ providing information on the difference between the internal control area and the cheek skin soft-tissue flap to assess 5 different characteristics: cyan, magenta, yellow, black, and luminosity. The control area was taken in order of preference from the ear-lobe skin, temple skin, nasal skin, and cervical skin to compare an area that was uninvolved in the surgical field and is most similar to the cheek soft tissues. The cheek flap was independently evaluated (**Figure 1**).

Following collection of both the control and cheek soft-tissue data, color change was objectively quantified with a previously validated formula, $x = (\Delta C^2 + \Delta Y^2 + \Delta M^2 + \Delta K^2 + \Delta L^2)^{1/2}$, in which Δ represents the difference in the individual characteristic between the study area and the internal control area

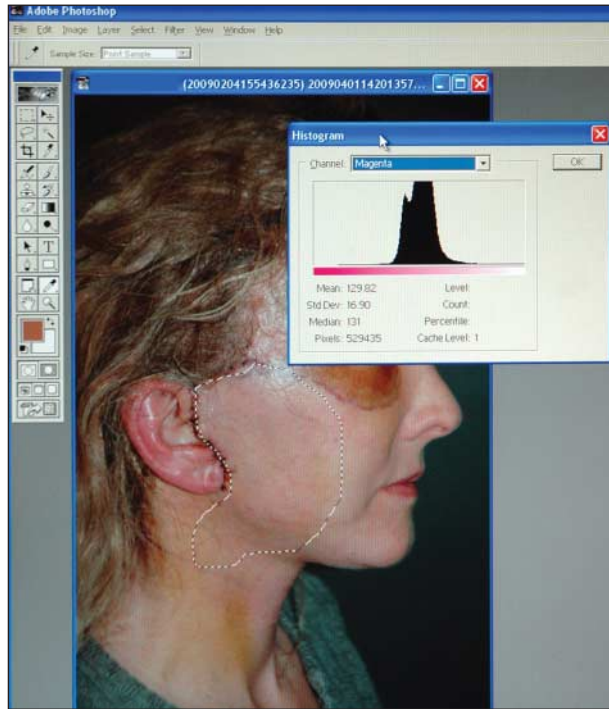


Figure 1. Outline of an area evaluated in a patient undergoing hyperbaric oxygen therapy is shown using Adobe Photoshop (Adobe Systems Inc, San Jose, California) in the CMYK color mode (see the "Methods" section).⁴

for each picture, resulting in a single unitless value, x . Following this, statistical analysis was performed for each postoperative point on PODs 1, 5, 7, and 10, using a paired t test assuming unequal variance.

Results. Thirteen female patients with a mean age of 59 years (age range, 47-71 years) were entered into the study, with 6 electing to undergo HBO therapy. Eleven patients underwent a deep plane face-lift, and 2 patients, 1 each in the control group and the treatment group, underwent an extended superficial musculoaponeurotic system face-lift. There were no surgical or medical complications. One patient in the control arm missed a single postoperative appointment on POD 5, with that value unavailable for analysis. Overall, 102 photographs and 1020 data points were analyzed. On POD 1, the average degree of color change in the cheek soft-tissue flap in the HBO group was 38.5 and in the control group was 43.7. This difference was not statistically significant ($P = .28$). The degree of color change in the HBO group on POD 5 was 39.0 and in the control group was 45.6. Again, this difference was not statistically significant ($P = .13$). On POD 7, the average degree of color change in the treatment group was 27.5 and in the control group was 42.2 ($P = .005$), with a 35% reduction in color change in the treatment group over the control group. The average degree of color change on POD 10 was 22.0 in the treatment group and 31.6 in the control group ($P = .03$), with an average of 30% reduction in color change in the treatment group when compared with the control group.

Figure 2 outlines the comparison between the patients undergoing HBO and the control patients.

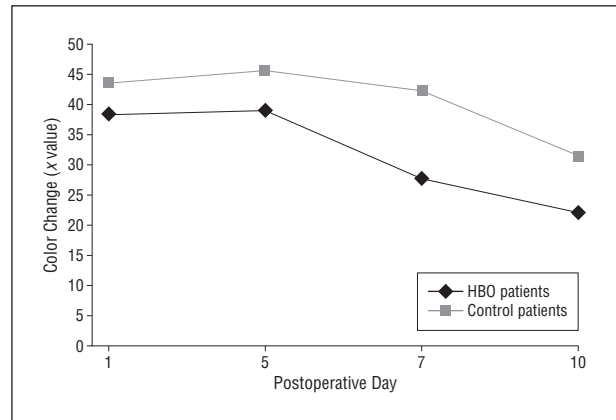


Figure 2. Difference in postoperative color change in patients undergoing hyperbaric oxygen (HBO) therapy. The difference was statistically significant on postoperative days 7 and 10 ($P = .005$ and $.25$, respectively).

Comment. A lot of research in homeopathy, surgical techniques, and adjunctive therapy has been performed to find newer, faster healing methods from surgical procedures.⁵ Patients undergoing facial surgery desire faster recovery to return to work and their personal lives sooner. There is a plethora of directed marketing techniques advertising minimally invasive surgery with short recovery periods to entice patients to undergo facial surgery, sometimes with unrealistic promises for exceptionally quick recoveries. Many homeopathy practitioners have used *A montana* owing to its multiple reported benefits, including improved healing, with contradicting results.⁶⁻¹⁰ Seeley et al⁴ objectively evaluated the effect of *A montana* on face-lift bruising, with their results demonstrating no statistically significant improvement in the degree of bruising postoperatively. As important to their reported results on the effect of *A montana* was the development of an objective, inexpensive, and easy-to-use computer model for assessing ecchymosis.

Hyperbaric oxygen therapy offers improved and faster wound healing in patients undergoing reconstructive surgery and those with chronic wounds. Recent research has demonstrated that HBO therapy improves wound neovascularization and epithelialization in vitro as well as blood flow to flaps and free composite graft and flap survivability in animal models.¹¹⁻¹³ It has also been shown to have a protective effect on ischemic reperfusion injury in animal models.¹⁴ To our knowledge, there has been no report of the use of HBO therapy and its effect on postoperative ecchymosis or its use in cosmetic surgery. Hyperbaric oxygen therapy offers patients a statistically significant, perioperative adjunctive therapy that decreases bruising in patients undergoing face-lift by 35% and 30% on PODs 7 and 10, respectively. Although the difference in color change on POD 5 was not statistically significant ($P = .13$), this most likely would become statistically significant with a larger sample size.

The major barrier to the use of HBO therapy is the time-consuming nature of this treatment as well as its cost. While there is a theoretical concern for postoperative bleeding with pressure changes in the chamber, our patients did not experience any postoperative hematomas by waiting until 48 hours after surgery for the first dive.

At \$225 per dive, the cost of this treatment would be approximately \$1100 if our protocol were followed.

Hyperbaric oxygen therapy offers patients an additional option for quicker recovery in face-lift surgery and potentially other cosmetic procedures. It should be included in the discussion with patients with limited available recovery time as an option for faster resolution of postoperative ecchymosis.

Benjamin C. Stong, MD
Andrew A. Jacono, MD

Author Affiliations: Kalos, the Atlanta Center for Facial Plastic Reconstructive and Laser Surgery, Atlanta, Georgia (Dr Stong); and Section of Facial Plastic and Reconstructive Surgery, North Shore University Hospital, Manhasset, New York, Division of Facial Plastic and Reconstructive Surgery, New York Eye and Ear Hospital, New York, New York, Department of Otolaryngology–Head and Neck Surgery, Albert Einstein College of Medicine, Bronx, New York, and New York Center for Facial Plastic and Laser Surgery, New York (Dr Jacono).

Correspondence: Dr Jacono, Department of Otolaryngology–Head and Neck Surgery, Albert Einstein College of Medicine, 990 Fifth Ave, New York, NY 10075 (drjacono@gmail.com).

Financial Disclosure: None reported.

Additional Contributions: The Hyperbaric Medicine of New York Center donated the HBO treatment session for this study. We thank its director, Ahmed Abu-Taleb, MD, for ensuring the good care of our patients.

1. Rah DK, Kim SC, Lee KH, Park BY, Kim DW. Objective evaluation of treatment effects on port-wine stains using L*a*b* color coordinates. *Plast Reconstr Surg*. 2001;108(4):842-847.
2. Currie CL, Monk BE. Can the response of port-wine stains to laser treatment be reliably assessed using subjective methods? *Br J Dermatol*. 2000;143(2):360-364.
3. Koster PH, Bossuyt PM, van der Horst CM, Gijsbers GH, van Gemert MJ. Assessment of clinical outcome after flashlamp pumped pulsed dye laser treatment of portwine stains: a comprehensive questionnaire. *Plast Reconstr Surg*. 1998;102(1):42-48.
4. Seeley BM, Denton AB, Ahn MS, Maas CS. Effect of homeopathic *Arnica montana* on bruising in face-lifts: results of a randomized, double-blind, placebo-controlled clinical trial. *Arch Facial Plast Surg*. 2006;8(1):54-59.
5. van der Horst CM, Koster PH, de Borgie CA, Bossuyt PM, van Gemert MJ. Effect of the timing of treatment of port-wine stains with the flash-lamp-pumped pulsed-dye laser. *N Engl J Med*. 1998;338(15):1028-1033.
6. Kaziro GS. Metronidazole (Flagyl) and *Arnica montana* in the prevention of post-surgical complications: a comparative placebo controlled clinical trial. *Br J Oral Maxillofac Surg*. 1984;22(1):42-49.
7. Taylor MA, Reilly D, Llewellyn-Jones RH, McSharry C, Aitchison TC. Randomised controlled trial of homeopathy versus placebo in perennial allergic rhinitis with overview of four trial series. *BMJ*. 2000;321(7259):471-476.
8. Vickers AJ, Fisher P, Smith C, Wyllie SE, Rees R. Homeopathic *Arnica 30x* is ineffective for muscle soreness after long-distance running: a randomized, double-blind, placebo-controlled trial. *Clin J Pain*. 1998;14(3):227-231.
9. Jacobs J, Springer DA, Crothers D. Homeopathic treatment of acute otitis media in children: a preliminary randomized placebo-controlled trial. *Pediatr Infect Dis J*. 2001;20(2):177-183.
10. Hart O, Mullee MA, Lewith G, Miller J. Double-blind, placebo-controlled, randomized clinical trial of homeopathic *arnica C30* for pain and infection after total abdominal hysterectomy. *J R Soc Med*. 1997;90(2):73-78.
11. Sander AL, Henrich D, Muth CM, Marzi I, Barker JH, Frank JM. In vivo effect of hyperbaric oxygen on wound angiogenesis and epithelialization. *Wound Repair Regen*. 2009;17(2):179-184.
12. Ulkür E, Karagoz H, Ergun O, Celikoz B, Yildiz S, Yildirim S. The effect of hyperbaric oxygen therapy on the delay procedure. *Plast Reconstr Surg*. 2007;119(1):86-94.
13. Li EN, Menon NG, Rodriguez ED, et al. The effect of hyperbaric oxygen therapy on composite graft survival. *Ann Plast Surg*. 2004;53(2):141-145.
14. Hong JP, Kwon H, Chung YK, Jung SH. The effect of hyperbaric oxygen on ischemia-reperfusion injury: an experimental study in a rat musculocutaneous flap. *Ann Plast Surg*. 2003;51(5):478-487.

Announcement

Visit www.archfacial.com. As an individual subscriber, references are more useful to you. References within the text are linked to the reference list, and vice versa, for easy browsing and navigation. Journal references are linked whenever possible to at least 1 of 3 locations to permit accessing the abstract and/or full text: (1) references to articles published in journals posted on HighWire are linked to free full text of articles (shown as FULL TEXT); (2) references to MEDLINE-indexed articles are linked to the free PUBMED abstract (PUBMED); and (3) references to articles published in journals that participate in CrossRef or ISI's Web of Science link to the full text (CrossRef or ISI). Articles linked through CrossRef or ISI may require you to log in for access.